RESEARCH ARTICLE OPEN ACCESS

Characterization of a Splice Variant in *FLNA* Associated With Periventricular Nodular Heterotopia

Yiyuan Zhang,[1,2,3,*] Yanru Huang,[4,5,*] Xianjing Huang,[1,2] Haijie Gao,[1,2] Jin Lin,[1,2] Xuemei He,[1,2] Ping Li,[1,2,†] and Libin Mei[1,2,†]

Neurol Genet 2026;12:e200356. doi:10.1212/NXG.0000000000200356

Correspondence
Dr. Mei
meilibinxm@163.com
or Prof. Li
saarc2001@sina.com

MORE ONLINE
Supplementary Material

Abstract

Background and Objectives

Periventricular nodular heterotopia (PNH) is a neuronal migration disorder caused by the failure of neurons to migrate properly to the cerebral cortex, characterized predominantly by epilepsy. Most PNH cases are associated with variants in *FLNA*, which is inherited in an X-linked pattern and exhibits a female predominance. Affected male patients typically experience prenatal or early postnatal lethality; only those with distal truncating or mosaic variants have been reported to survive. In this study, we aimed to characterize the clinical and genetic features of a Chinese pedigree with PNH.

Methods

Whole-exome sequencing (WES) was performed on genomic DNA isolated from the peripheral blood. Mosaicism levels were quantified using droplet digital PCR (ddPCR), transcriptomic alterations were analyzed by RNA sequencing (RNA-seq), and splicing defects were investigated via a minigene splicing assay.

Results

WES analysis identified a novel splicing variant (NM_001110556.2: c.4599-2A > G) in the *FLNA* gene of the proband. Sanger sequencing revealed a double peak at the same site in her father. Droplet digital PCR confirmed paternal somatic mosaicism, with variant allele frequencies of 65.98% in the blood, 60.38% in the sperm, and 28.95% in the buccal mucosa. RNA-seq and minigene assays detected an aberrant transcript containing a 10 bp deletion at the 5′ end of exon 28. The minigene assay further revealed 2 mutant transcripts: one with the same 10 bp deletion and another with complete skipping of exon 28.

Discussion

This study expands the phenotypic and genetics spectrum of PNH and demonstrates a dual PNH phenotype with a bi-transcript mechanism. It also provides clinical evidence of mosaic inheritance and tissue-specific mosaicism, offering valuable implications for genetic counseling and prenatal diagnosis.

Introduction

PNH is a neurodevelopmental brain malformation characterized by failure of the gray matter to properly migrate to the cerebral cortex during embryonic development. This results in ectopic localization around the ventricular ependyma.[1] MRI serves as the primary diagnostic tool, showing bilateral periventricular gray matter nodules with a signal intensity similar to that of

*These authors contributed equally to this work as co-first authors.

†These authors contributed equally to this work as co-corresponding authors.

[1]Department of Reproductive Medicine, Women and Children's Hospital, School of Medicine, Xiamen University, Fujian, China; [2]Xiamen Key Laboratory of Reproduction and Genetics, Women and Children's Hospital, School of Medicine, Xiamen University, Fujian, China; [3]School of Life Sciences, Xiamen University, Fujian, China; [4]Department of Central Laboratory, Women and Children's Hospital, School of Medicine, Xiamen University, Fujian, China; and [5]School of Public Health, Xiamen University, Fujian, China.

The Article Processing Charge was funded by the General Fund Project of Xiamen Natural Science Foundation.

This is an open access article distributed under the terms of the Creative Commons Attribution-Non Commercial-No Derivatives License 4.0 (CCBY-NC-ND), where it is permissible to download and share the work provided it is properly cited. The work cannot be changed in any way or used commercially without permission from the journal.

Copyright © 2026 The Author(s). Published by Wolters Kluwer Health, Inc. on behalf of the American Academy of Neurology.

Downloaded from https://www.neurology.org by 104.28.195.185 on 15 March 2026

Glossary

ABD = actin binding domain; **ddPCR** = droplet digital PCR; **NMD** = nonsense-mediated mRNA decay; **OB** = osteoblast; **OC** = osteoclast; **PNH** = periventricular nodular heterotopia; **PTC** = premature termination codon; **RNA-seq** = RNA sequencing; **WES** = whole-exome sequencing; **XCI** = X-chromosome inactivation.

normal cortical gray matter.[2,3] Its primary clinical manifestation is epilepsy, which is often accompanied by intellectual disabilities and learning difficulties.[2,3] PNH is genetically heterogeneous and is linked to variants in multiple genes, including *ARFGEF2*, *ERMARD*, *NEDD4L*, *ARF1*, and *MAP1B*, as well as abnormalities in chromosome 5. Among these, pathogenic variants in *FLNA* are the most common genetic causes.[4]

FLNA is located at Xq28 and comprises 47 exons,[5] encoding a 280 kDa actin binding protein, called filamin A. The N-terminal region contains an actin binding domain (ABD) and a rod-like structure composed of 24 immunoglobulin-like repeats. ABD interacts with actin to stabilize the cytoskeletal architecture and plays crucial roles in maintaining cell shape, migration, and transmitting mechanical force. *FLNA* regulates cellular migration and extension processes via interactions with several signaling proteins, including small GTPases Rac/Rho, TRAF2, integrins, and BRCA2.[6-8] This gene possesses at least 2 transcription initiation sites (ENST00000369850.8 and ENST00000610817.4) that use distinct promoters and demonstrate tissue-specific expression.[6-8] Rat *FLNA*-knockdown models exhibit impaired neuronal migration and elevated epileptic susceptibility.[9] Female patients are predominant in *FLNA*-related PNH, because of frequent fetal lethality in hemizygous male patients, although surviving male participants with distal truncating variants or somatic mosaicism have been reported.[10,11]

In this study, we describe a case of familial PNH caused by a novel *FLNA* variant. The proband presented with PNH accompanied by a developmental delay. WES identified an *FLNA* splice-site variant (c.4599-2A > G). The proband's father demonstrated somatic mosaicism, with tissue-specific mosaic ratios of 65.98% in the peripheral blood, 60.38% in the semen, and 28.95% in the buccal mucosal cells. Reverse transcription-polymerase chain reaction (RT-PCR) and minigene assays showed that this variant disrupts normal mRNA splicing, producing 2 aberrant transcripts. This case expands the *FLNA* variant and phenotypic spectrum, showing PNH's dual phenotype with growth delay, potentially attributable to the production of 2 mutant transcripts caused by c.4599-2A > G variant.

Methods

Molecular Genetic Analyses

Genomic DNA was extracted from peripheral blood samples. WES was conducted using a SureSelect Human All Exon kit V6 (Agilent Technologies, Santa Clara, CA) on the Illumina Novaseq 6,000 platform. Sequenced reads were mapped to the human reference genome (UCSC hg19) using a BWA aligner (Burrows-Wheeler alignment tool, version 0.7.15). Software such as SAMtools was used to find and analyze SNVs and indels in the sequencing data based on the BAM results compared with genomic reference sequences. *FLNA* reference transcript NM_001110556.2 (RefSeq). The variants were screened and annotated using the human genome information from OMIM, ClinVar, HGMD, and other databases, according to the guidelines of the American College of Medical Genetics and Genomics. Polyphen-2, SIFT, and MutationTaster were used to predict the suspicious variant pathogenicity.

Digital PCR

Peripheral blood samples (5 mL) were collected from the father using standard blood collection tubes. The semen was collected once and stored in sterile semen containers. Buccal mucosal specimens were collected using cotton swabs and stored in centrifuge tubes containing saline. Hair samples (5–10 strands with intact follicles) were collected and stored in centrifuge tubes. Droplet digital PCR (ddPCR) was performed using the Bio-Rad Q ×200 Droplet Digital PCR System. Each reaction mixture (20-μL total volume) contained 10-μL ddPCR Supermix for Probes (No dUTP, Bio-Rad), 250 nM each of forward (5′-AGGCTGGATGCTGAG AACC-3′) and reverse (5′-CTTCACCTTGCTGGCATC AT-3′) primers, 250 nM each of VIC- and FAM-labeled MGB probes (reference-type: 5′-CCTCACAGCCCCTT-3′; variant-type: 5′-CCTCACGGCCCCT-3′), 2-μL genomic DNA template, and 3.4-μL nuclease-free water. The mixture was subsequently emulsified into droplets using a droplet generator. Thermal cycling conditions were as follows: 95°C for 10 minutes (initial denaturation), 40 cycles of 95°C for 30 seconds (denaturation), 60°C for 1 minute (annealing/extension), and 12°C for 5 minutes (final extension). Fluorescent signals were quantified using a Q ×200 Droplet Reader. QuantaSoft (Version 1.7.4, Bio-Rad) was used for data analysis.

RNA Analysis

Peripheral blood (5 mL) were collected into EDTA-anticoagulated tubes. Total RNA was extracted from the peripheral blood using the Blood (Liquid Sample) Total RNA Rapid Extraction Kit (TR121-50; Genston Biotech). Residual genomic DNA was removed, and cDNA was synthesized using the PrimeScript FAST RT Reagent Kit with gDNA Eraser (RR092A, TaKaRa) according to the manufacturer's instructions. PCR amplification of cDNA was performed with

Downloaded from https://www.neurology.org by 104.28.195.185 on 15 March 2026

PrimerSTAR MAX DNA Polymerase (R045A, TaKaRa). The resulting amplicons were resolved by agarose gel electrophoresis, gel-purified, and subjected to Sanger sequencing (eMethods, eFigure 1). The gel-purified PCR products were ligated into the pMD18-T vector (Takara) for TA cloning. The ligation mixtures were then transformed into competent E. coli DH5α cells. Single colonies were screened by colony PCR, and positive clones were subjected to Sanger sequencing.

Minigene Assay

The Minigene assay was performed by BioEagle Biotech Co., Ltd. (Wuhan, China). Two pairs of nested primers—12261-*FLNA*- F(5′- TCAAAGTGCAAGGGCCCAAA-3′) and 14313 -*FLNA*- R (5′-CTGGTCACTGAGCAGATGTG-3′) as well as 12471-*FLNA*-F (5′-CTGGAACTGTCCTGGGAATC-3′) and 14087-*FLNA*-R (5′-AAGATCCCGAGACCCCAAAG-3′)—were designed to amplify the genomic region spanning the exon 27–29 of *FLNA* from the genomic DNA. PCR-amplified fragments were cloned into the minigene vector pcDNA3.1 (eFigure 2). The recombinant vectors were subsequently transfected into HeLa and 239T cells. Total RNA was extracted 48 hours post-transfection using TRIzol reagent (9,109, TaKaRa). Finally, RNA-seq and Sanger sequencing were performed to analyze the recombinant vector splicing.

Standard Protocol Approvals, Registrations, and Patient Consents

The Internal Ethics Committee of Women and Children's Hospital, Xiamen University approved this study, and informed consent was obtained from all participants. Clinical information was abstracted from the patients' medical records.

Data Availability

The raw data supporting the conclusions of this article will be made available by the authors on request.

Results

Clinical Presentation

The family described in this study is of Chinese Han ethnicity and originates from Xiamen, Fujian Province, China. The proband (Figure 1A) is a 7-year-old girl who was born at full term (37 weeks of gestation) via spontaneous vaginal delivery, with no reported perinatal asphyxia. Her birth weight was 2.0 kg and length was 42 cm. A brain MRI performed on the third postnatal day revealed agenesis of the corpus callosum, bilateral subependymal heterotopia, and an occipital arachnoid cyst. At the age of 7 years, a follow-up cranial MRI confirmed the presence of subependymal heterotopia (Figure 1B). Chromosomal examination of the proband revealed the 46, XX karyotype. Genetic testing was conducted at 5 years of age because of the proband's short stature.

The proband's mother underwent prenatal ultrasonography at 23 weeks of the first pregnancy, which revealed fetal brain abnormalities. Subsequent fetal MRI revealed abnormal signals in the bilateral lateral ventricular walls, implying possible gray matter heterotopia, partial agenesis of the corpus callosum, dilation of the posterior horns of the lateral ventricles, and an enlargement of the cisterna magna. In addition, placental anomalies, including anterior- and paddle-shaped placentas, were noted. The pregnancy was terminated because of these findings. No genetic testing was performed on the fetus. The mother exhibited no history of infection, fever, medication use, radiation exposure, or vaginal bleeding during early pregnancy.

The proband's father, a 36-year-old man, had a height of 171 cm and weighed 50 kg. The father had normal intelligence, and no abnormalities were detected on cranial MRI.

WES Analysis

WES identified a heterozygous c.4599-2A > G variant in *FLNA* at the intron-27 3′ splice acceptor in the proband. Sanger sequencing confirmed the presence of this variant in the peripheral blood of the proband and the father, showing a heterozygous state in the proband and a hemizygous mosaic state in the father, whereas the mother was identified as the wild type (Figure 1C). This variant is classified as likely pathogenic (PVS1 + PM2), according to the American College of Medical Genetics and Genomics variant classification guidelines because its allele frequency is <0.0005 in the population databases. This variant has not been previously reported and was not found in the HGMD, ClinVar, dbSNP, 1000 G, ExAC, ESP6500, or any other SNP databases.

Digital PCR

The ddPCR analysis showed substantial differences in the chimerism levels of the *FLNA* c.4599-2A > G variant across various tissues in the proband's father. The variant allele frequencies were 65.98% in the peripheral blood (Figure 2A), 60.38% in the semen (Figure 2B), and 28.95% in the buccal mucosal cells (Figure 2C). No suitable candidate cells were identified for analysis of the hair follicle samples (Figure 2D). These findings provided direct evidence of somatic mosaicism in the proband's father.

RNA Analysis

PCR analysis of the RNA extracted from the proband and the parents showed a single band for all samples (Figure 3A). However, Sanger sequencing revealed a single peak in the mother and proband, consistent with the expected size of the normally spliced transcript (522 bp, designated isoform a). By contrast, the sequencing results of the father showed double peaks (Figure 3B), indicating the presence of 2 distinct splicing products (isoforms a and b). TA cloning was performed gel-purified cDNA PCR products from the father to further characterize these transcripts. Among the 30 individual bacterial colonies screened, Sanger sequencing of 7 clones identified 6 clones containing a normally spliced transcript (isoform a) and 1 clone carrying an aberrantly spliced transcript (isoform b) (Figure 3, C and D). The

Downloaded from https://www.neurology.org by 104.28.195.185 on 15 March 2026

Figure 1 A Splice Variant in *FLNA* Causes PNH

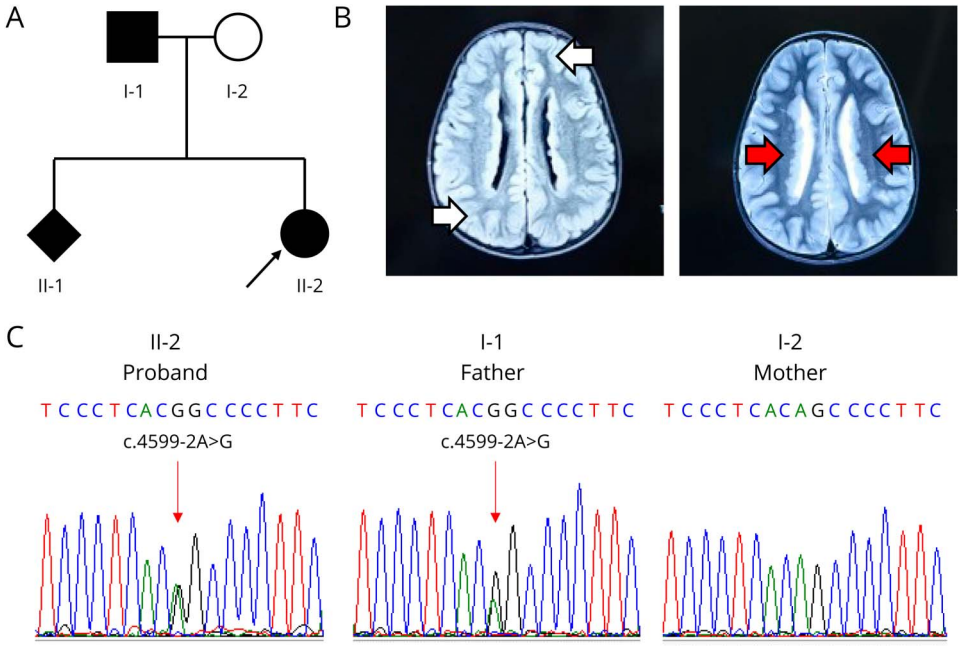

(A) Pedigree of the family. The black arrow indicates proband (II 2) (B) Brain MRI showing generalized cortical atrophy in II 2. White arrows to indicate the enlarged sulci. Red arrows indicated multiple nodular gray matter signal shadows in bilateral lateral ventricles. (C) Sanger sequencing of the family members I 1, I 2, and II 2 (the proband). PNH = periventricular nodular heterotopia.

Figure 2 ddPCR Analysis of Multiple Samples

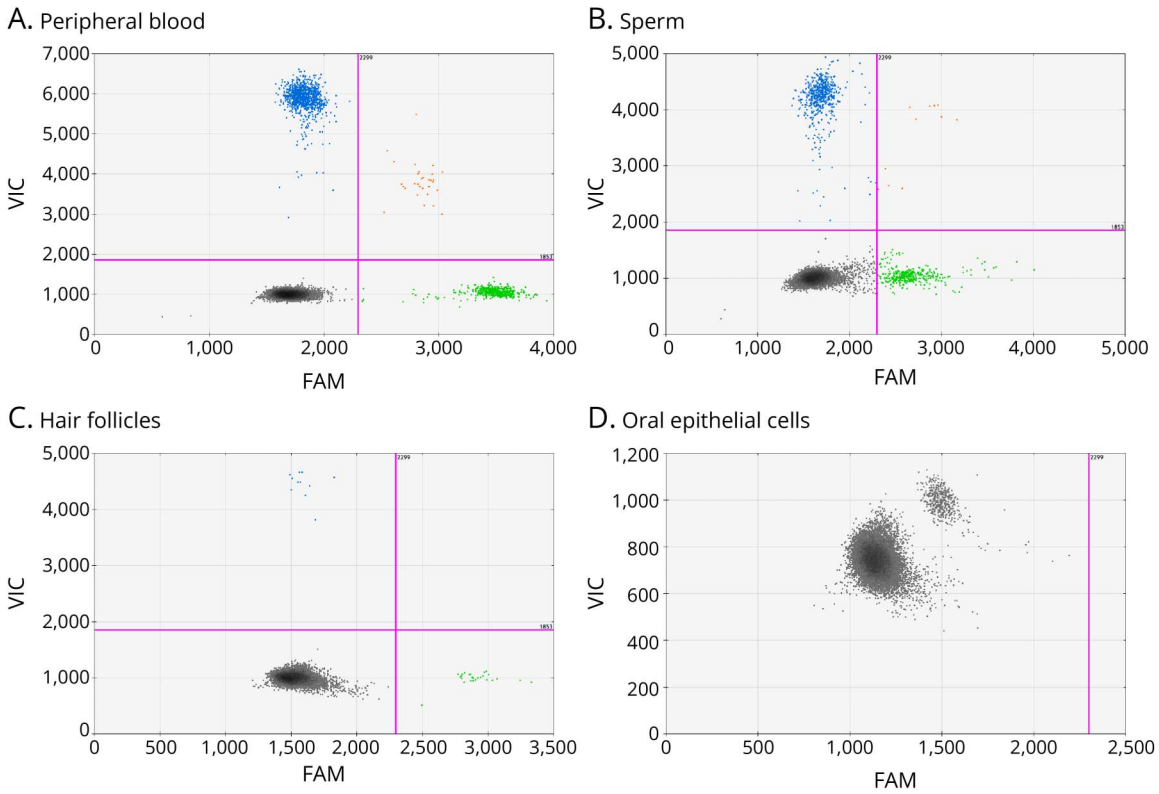

FLNA reference-type and variant-type (c.4599-2A > G) alleles were identified in multiple samples (A peripheral blood, B sperm, C hair follicles, and D oral epithelial cells) from the proband's father using droplet digital PCR (ddPCR). The x-axis (FAM channel) and y-axis (VIC channel) represent fluorescence signal intensities. The purple threshold lines indicate the fluorescence cutoff values. Blue droplets correspond to the variant allele (c.4599-2G), green droplets to the wild-type allele (c.4599-2A), while gray or yellow droplets represent rain or unclassified signals. No valid droplets were obtained from the oral epithelial cells sample.

Downloaded from https://www.neurology.org by 104.28.195.185 on 15 March 2026

Figure 3 Results of the c.4599-2A>G Variant on the mRNA Splicing

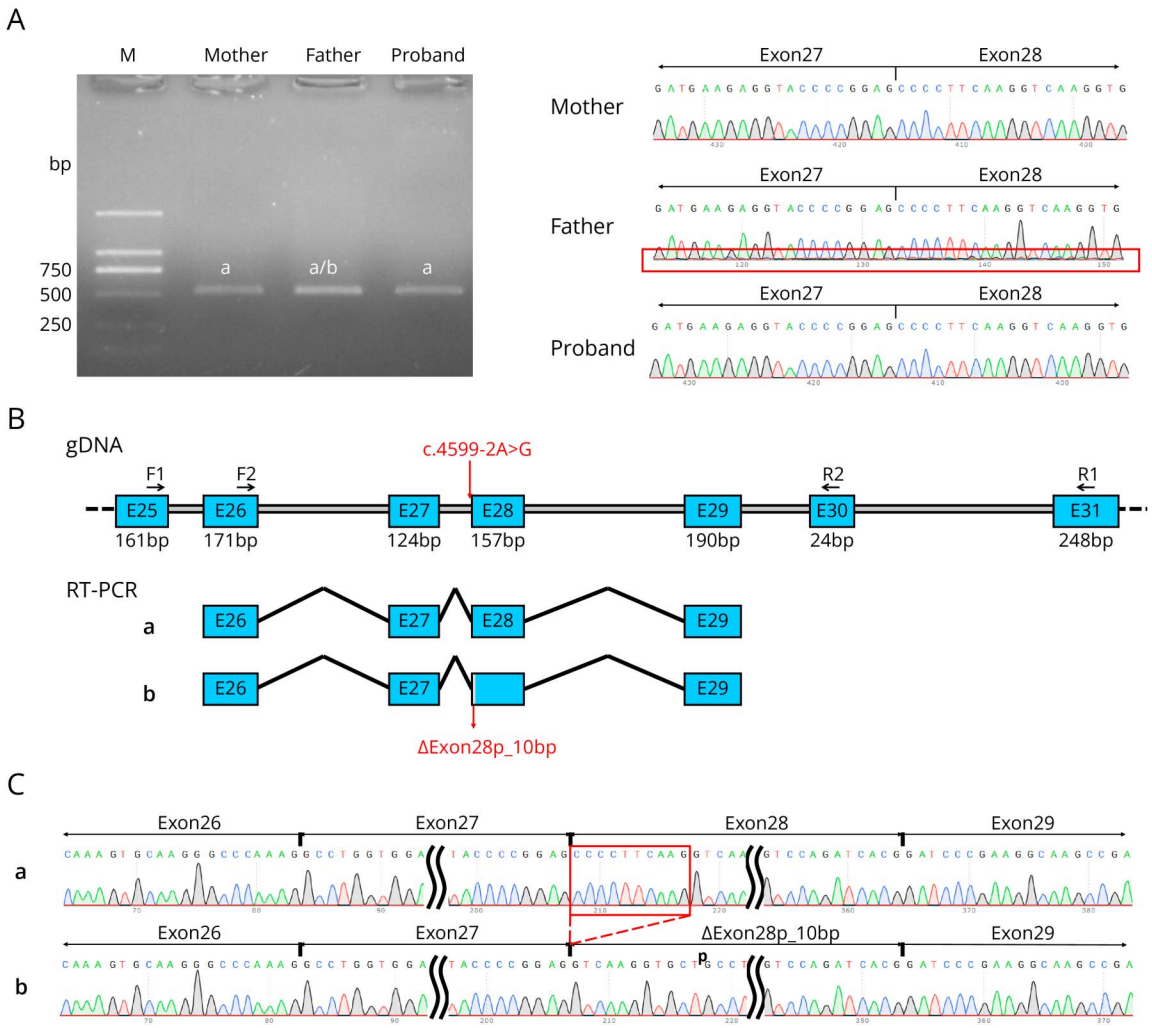

(A) Agarose gel electrophoresis of the reverse transcription PCR products from the proband and the parents. Proband and the parents all showed a single PCR band (B) Result of the reverse transcription PCR analysis. The father's sequencing result showed weak double peaks, whereas the proband and the mother demonstrated single peaks. (C) Schematic representation of the primer design and splicing pattern. The red arrow indicates the variant site. (D) Sanger sequencing chromatograms corresponding to the splicing isoforms A and B.

normal splicing pattern (isoform a) included Exon 26 (171 bp)—Exon 27 (124 bp)—Exon 28 (157 bp)—Exon 29 (190 bp). By contrast, the aberrant splicing transcript (isoform b) showed a 10-bp deletion at the left side of Exon 28, leading to an altered splicing pattern: Exon 26 (171 bp)—Exon 27 (124 bp)—△Exon 28 (147 bp)—Exon 29 (190 bp). These results confirmed that the *FLNA* c.4599-2A > G variant disrupts normal mRNA splicing.

Minigene Analysis

We performed a minigene-splicing assay to determine whether 4599-2A > G influenced *FLNA*'s splicing in the genomic region spanning Exons 27–29 in *FLNA* (Figure 4A). We obtained 2 different minigenes by subcloning Exons 27–29 into the pcDNA3.1 vector: pcDNA3.1-*FLNA*–WT and pcDNA3.1-*FLNA*-mut. Both minigenes were transfected into HeLa and 293T cells, and reverse transcription PCR was used to analyze the resultant transcripts. Subsequently, agarose gel electrophoresis of the PCR products from pcDNA3.1-*FLNA*–WT revealed a single PCR band (isoform a), whereas the PCR products from pcDNA3.1- *FLNA*–mut showed 2 bands (isoforms b and c) (Figure 4B).

Sanger sequencing was performed on the wild-type isoform a and mutant isoforms b and c. The sequencing results showed that the wild-type isoform a followed the expected splicing pattern: Exon 27 (124 bp)—Exon 28 (157 bp)—Exon 29 (190 bp). Mutant isoform b demonstrated a 10-bp deletion on the left side of Exon 28, leading to the following aberrant splicing pattern: Exon 27 (124 bp)—△Exon 28 (147 bp)—Exon 29 (190 bp). Mutant isoform c showed exon skipping, with Exon 28 being entirely absent, resulting in the splicing pattern: Exon 27 (124 bp)—Exon 29 (190 bp) (Figure 4, C and D).

Downloaded from https://www.neurology.org by 104.28.195.185 on 15 March 2026

Figure 4 Minigene Assay Results in the pcDNA3.1 Vector

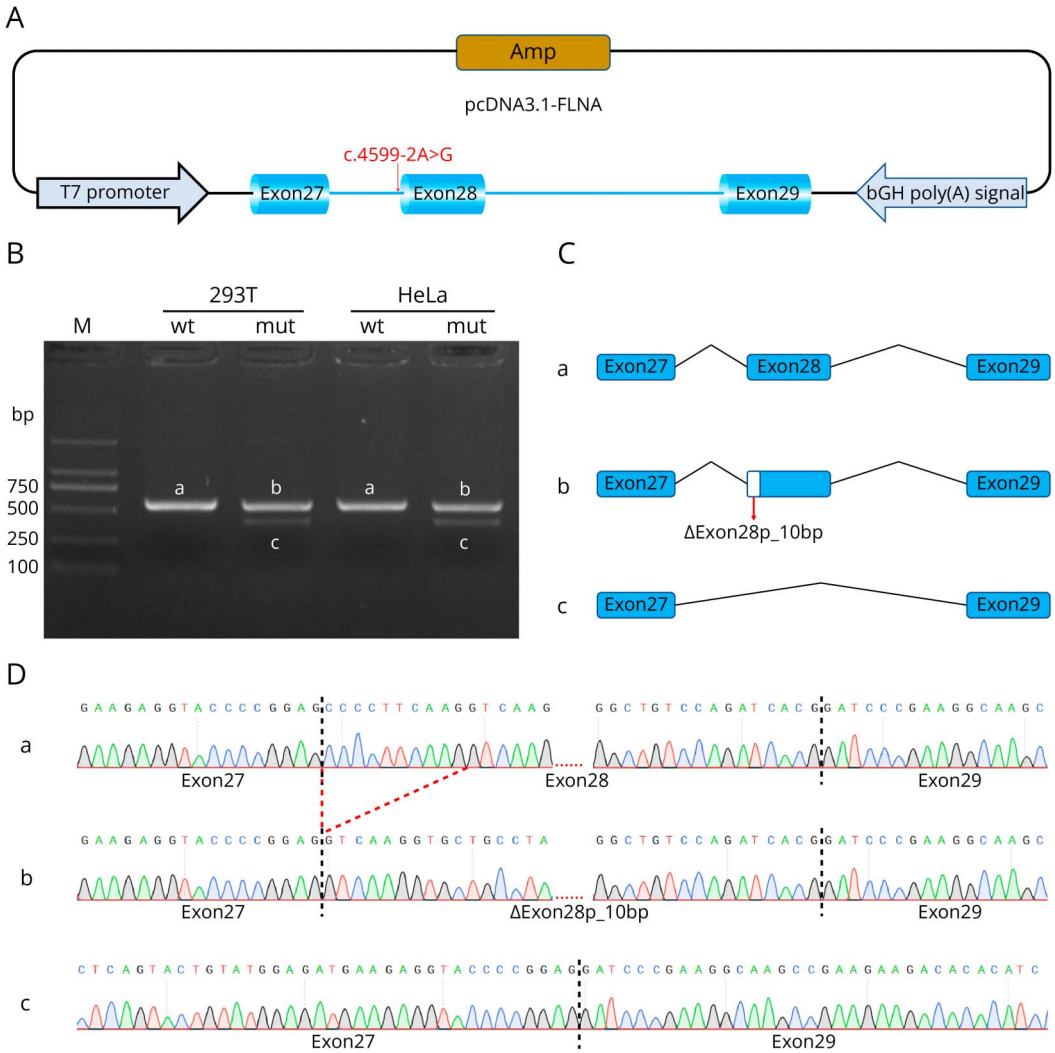

(A) Schematic diagram of the minigene constructs. (B) Agarose gel electrophoresis of the reverse transcription PCR products from the minigene assays in the 293T and HeLa cells, with detected isoforms labeled as a, b, and c. (C) Schematic representation of the splicing patterns in the minigene assay. (D) Sanger sequencing chromatograms corresponding to the splicing isoforms.

Minigene assay results confirmed that the *FLNA* c.4599-2A > G variant disrupts normal mRNA splicing, leading to 2 distinct aberrant splicing events: (1) a 10-bp deletion on the left side of Exon 28 and (2) complete skipping of Exon 28.

Discussion

In this study, we report a Chinese family with PNH carrying the *FLNA* c.4599-2A > G splicing variant. This variant situated at the −2 position of intron 27 affects the canonical splice site. Reverse transcription PCR was conducted on the peripheral blood RNA from the proband and the parents to investigate its effect on gene expression. Aberrant transcripts were observed at low levels only in the mosaic father but not in the proband or the unaffected mother. Given that *FLNA* is an X-linked gene and previous studies have reported random X-chromosome inactivation (XCI) within families,[12] we hypothesized that XCI and nonsense-mediated mRNA decay (NMD) contribute to the absence of detectable variant transcripts in the proband's blood. XCI is tissue specific,[13] and the variant allele is likely inactivated in the peripheral blood while being preferentially expressed in the brain.

We conducted an minigene assay to further confirm splicing changes undetectable by RNA-seq, which showed 2 aberrant transcripts: 1 with a 10 bp deletion at the 5′ end of exon 28 and another with exon 28 skipping. Both transcripts contained premature termination codons (PTCs) that likely triggered NMD. This mechanism may explain the low aberrant transcript levels noted in the peripheral blood of the mosaic father.

Electrophoresis analysis (Figure 4B) clearly showed that the transcript with a 10 bp deletion at the 5′ end of exon 28 was more abundant than the exon 28-skipped transcript. Similarly,

Downloaded from https://www.neurology.org by 104.28.195.185 on 15 March 2026

only the 10 bp deletion transcript was detected at low levels in the peripheral blood of the father, implying that this transcript is likely the predominant splicing product. This indicates that the splicing machinery preferentially uses a nearby cryptic splice site rather than skipping the entire exon. This preference may explain the higher abundance of the 10 bp deletion transcript compared with the exon-skipped transcript and why only the deletion transcript was detected in the peripheral blood of the father. In addition, a 2004 study [14] reported a female patient with PNH and oto-palato-digital syndrome caused by a single *FLNA* variant, in whom 2 distinct aberrant transcripts were identified. This result further supports the notion that *FLNA* splice variant can result in several transcript isoforms that contribute to phenotypic variability.

We identified 2 aberrant transcripts resulting from the *FLNA* c.4599-2A > G: c.4599_4608del (p.Ser1533Argfs13) and c.4599_4755del (p.Ser1533Argfs28) by blood mRNA analysis and minigene assays. Both transcripts introduce a frameshift, producing PTCs within exons 28 and 29, potentially resulting in truncated proteins with amino acids 1,544 and 1,559, respectively.

Filamin A comprises 24 immunoglobulin-like repeat domains (Figure 5A). The mutated region influences repeat 13, a domain that particularly recognizes migfilin, a regulatory factor of the cytoskeleton (Figure 5B). Migfilin interacts with multiple filamins (e.g., filamins A, B, and C) and actin, which are necessary for maintaining cytoskeletal integrity. Exon 28 truncation leads to the loss of critical filamin A domains, including repeat 17, which particularly binds to the platelet receptor glycoprotein, and repeats 17, 19, 21, and 23, which contain conserved integrin binding sites. Integrins are transmembrane proteins that mediate interactions between cells and the extracellular matrix and play a critical role in cell adhesion and signal transduction.[15] Because filamin A is a key intracellular binding partner of integrins, the absence of these conserved integrin binding domains may impair integrin interactions. This subsequently affects cellular adhesion and signal transduction processes.

In this family, the father did not exhibit PNH-related symptoms, although large fragment transcript deletions are typically linked to considerable protein dysfunction and more severe disease phenotypes. This may be attributed to the mosaic variant status. In *FLNA*-associated disorders, male patients with mosaicism often present with milder phenotypes.[10] Thus, we hypothesized that the clinical manifestations in male patients with *FLNA* variant may be influenced by the mosaicism degree. Reports of male patients with pathogenic *FLNA* variants are relatively rare, and epilepsy is a common feature among the documented mosaic cases. Elena et al.[10] reported a 49-year-old male patient who developed epilepsy at the age of 15 years with an *FLNA* c.1692-2A > G variant present at frequencies of 42% in blood DNA and 69% in hair DNA. Similarly, Guerrini[16] described another male patient of the same age who presented with pes cavus and bifid epiglottis at birth, followed by the onset of epilepsy at 15 years of age. The *FLNA* c.1692-2 A > G variant was detected at frequencies of 42% in the leukocytes and 69% in hair follicle DNA. These cases provide evidence supporting the potential correlation between mosaicism levels and clinical severity, reinforcing our hypothesis that the ratio of mosaic variant may affect the phenotypic presentation in male patients with pathogenic *FLNA* variants.

In this family, the father, who lacks PNH-related phenotypes, has a heterozygous daughter who presents with considerable growth delay. At birth, the daughter weighed only 2 kg, which was notably, lower than that of the age-matched peers. The daughter's MRI resonance imaging showed gray matter heterotopia and corpus callosum agenesis, resulting in PNH diagnosis. Although the daughter had not yet developed epilepsy, this may have been age dependent, and we plan to conduct further follow-up.

Growth delay is not a typical PNH feature but represents a unique manifestation in this case, which is relatively rare in previous PNH reports. Previous studies have suggested a potential link between pathogenic *FLNA* variants and growth delay. A 2005 study was the first to report this association,[17]

Figure 5 Schematic Representation of the Domain Architecture of Filamin A and the Location of Identified Variants (Not to Scale)

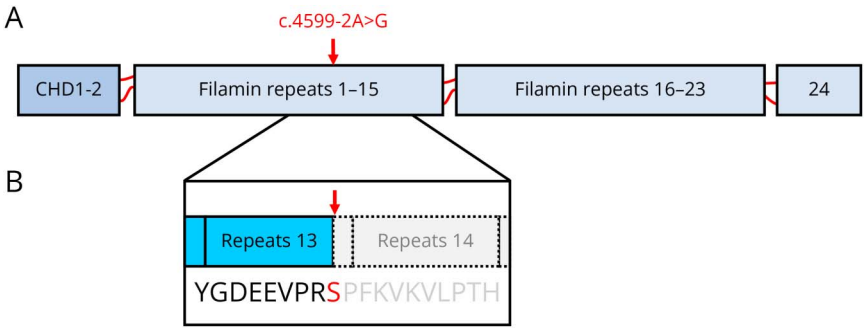

(A) Filamin A comprises an N-terminal actin binding domain (ABD), which includes 2 calponin-homology subdomains (CH1 and CH2). This is followed by a rod region composed of 24 immunoglobulin-like (Ig) repeats. Two hinge segments (highlighted in red) interrupt the rod structure: hinge 1 is located between repeats 15 and 16, and hinge 2 between repeats 23 and 24. (B) The position of the c.4599−2A > G variant is indicated by a red arrow within repeat 13.

Downloaded from https://www.neurology.org by 104.28.195.185 on 15 March 2026

which was potentially associated with skeletal phenotypes resulting from pathogenic *FLNA* variants. Filamin A, which plays a role in skeletal development by forming dimers with filamin B, may result in skeletal abnormalities.[18] This mechanism involves Rho GTPase activity regulation, which influences actin cytoskeleton assembly and, consequently, osteoblast (OB) and osteoclast (OC) functions. OBs are responsible for bone formation and mineralization, whereas OCs mediate bone resorption and remodeling. *FLNA* accumulates in both cell types and interacts with low-density lipoprotein receptor–related protein 6 to inhibit β-catenin expression. This enhances the osteoclastogenic gene expression of the dependent on nuclear factor of activated T cell 1, thereby suppressing bone formation and promoting OC activity.[19] Furthermore, a 2006 study[20] using *Flna* knockout mouse models supported the link between pathogenic *FLNA* variants and skeletal abnormalities, showing defects such as sternal malformations and cleft palate.

These results suggest that pathogenic *FLNA* variants may contribute to the classic neuropathologic features of PNH and may influence skeletal development, resulting in growth delay and associated pathologic phenotypes.

Furthermore, pathogenic *FLNA* variants have been shown to typically result in neurologic or skeletal phenotypes but not both. This phenomenon may be due to various pathogenic *FLNA* variants, which produce distinct mutant proteins that variably affect filamin A function. These altered proteins may influence the key pathways involved in neuronal migration and OB development via various molecular mechanisms.

However, some case reports have indicated that this mutual exclusivity may not be absolute. For example, a 2011 study[21] described 2 male children diagnosed with hydrocephalus and PNH who also showed skeletal abnormalities, including flat facies, spatulate fingertips, short and broad phalanges and metacarpals, bowed radii, and wrist joint dislocations. Furthermore, a 2004 study[22] reported on a female patient with PNH and osteodysplasia of the pelvis, showing a dual phenotype affecting neurologic and skeletal development. These cases underscore the potential for overlapping and complex phenotypic manifestations of *FLNA* variants, suggesting that a more nuanced understanding of genotype-phenotype correlations is essential when investigating *FLNA*-associated disorders.

In conclusion, this study reports a family affected by an *FLNA* splicing variant, comprising a mosaic father without PNH-related phenotypes and the father's daughter who presented with PNH and growth delay. These results provide new insights into the effect of pathogenic *FLNA* variants in male patients, especially in the context of distal truncating and mosaic variants. We hypothesized that alternative splicing events induced by pathogenic *FLNA* variants may be key factors contributing to the observed phenotypic variability. These results enhance our understanding of *FLNA* gene function and expand the genetic and phenotypic spectra of *FLNA*-related disorders. However, our findings are based on a single family, and further studies involving larger cohorts and advanced molecular techniques are needed to validate these observations.

Acknowledgment

The authors would like to thank patients and their families for their support, as well as the editor and reviewers for their constructive feedback.

Author Contributions

Y. Zhang: drafting/revision of the manuscript for content, including medical writing for content; major role in the acquisition of data; study concept or design; analysis or interpretation of data. Y. Huang: drafting/revision of the manuscript for content, including medical writing for content; study concept or design. X. Huang: major role in the acquisition of data. H. Gao: major role in the acquisition of data; study concept or design. J. Lin: study concept or design. X. He: analysis or interpretation of data. P. Li: drafting/revision of the manuscript for content, including medical writing for content. L. Mei: drafting/revision of the manuscript for content, including medical writing for content; major role in the acquisition of data; study concept or design; analysis or interpretation of data.

Study Funding

This study was supported by the General Fund Project of Xiamen Natural Science Foundation (Grant no.3502Z202373117) and the General Fund Project of Fujian Natural Science Foundation (Grant no. 2023J011611, 2024J011342, and 2023J05269).

Disclosure

The authors report no relevant disclosures. Go to Neurology.org/NG for full disclosure.

Publication History

Received by *Neurology® Genetics* June 2, 2025. Accepted in final form December 23, 2025. Submitted and externally peer reviewed. The handling editor was Deputy Editor Antonella Spinazzola, MD.

References

1. Fox JW, Lamperti ED, Ekşioğlu YZ, et al. Mutations in filamin 1 prevent migration of cerebral cortical neurons in human periventricular heterotopia. *Neuron.* 1998;21(6):1315-1325. doi:10.1016/s0896-6273(00)80651-0
2. Parrini E, Ramazzotti A, Dobyns WB, et al. Periventricular heterotopia: phenotypic heterogeneity and correlation with Filamin A mutations. *Brain.* 2006;129(Pt 7):1892-1906. doi:10.1093/brain/awl125
3. Oberoi-Khanuja TK, Karreman C, Larisch S, Rapp UR, Rajalingam K. Role of melanoma inhibitor of apoptosis (ML-IAP) protein, a member of the baculoviral IAP repeat (BIR) domain family, in the regulation of C-RAF kinase and cell migration. *J Biol Chem.* 2012;287(34):28445-28455. doi:10.1074/jbc.M112.341297
4. Sarkisian MR, Bartley CM, Rakic P. Trouble making the first move: interpreting arrested neuronal migration in the cerebral cortex. *Trends Neurosci.* 2008;31(2):54-61. doi:10.1016/j.tins.2007.11.009
5. Patrosso MC, Repetto M, Villa A, et al. The exon-intron organization of the human X-linked gene (FLN1) encoding actin-binding protein 280. *Genomics.* 1994;21(1):71-76. doi:10.1006/geno.1994.1226
6. Garcia JM, Pepin S, Lagarde N, et al. Heterosubtype neutralizing responses to influenza A (H5N1) viruses are mediated by antibodies to virus haemagglutinin. *PLoS One.* 2009;4(11):e7918. doi:10.1371/journal.pone.0007918
7. Lasunskaia E, Ribeiro SC, Manicheva O, et al. Emerging multidrug resistant Mycobacterium tuberculosis strains of the Beijing genotype circulating in Russia express

Downloaded from https://www.neurology.org by 104.28.195.185 on 15 March 2026

a pattern of biological properties associated with enhanced virulence. *Microbes Infect.* 2010;12(6):467-475. doi:10.1016/j.micinf.2010.02.008
8. Weaver CD, Gundersen V, Verdoorn TA. A high affinity glutamate/aspartate transport system in pancreatic islets of Langerhans modulates glucose-stimulated insulin secretion. *J Biol Chem.* 1998;273(3):1647-1653. doi:10.1074/jbc.273.3.1647
9. Sykes JA, Lubega J, Ezetendu C, Verma R, O'Connor B, Kalyanaraman M. Asymptomatic complete atrioventricular block in a 13-year-old girl. *Pediatr Emerg Care.* 2011;27(11):1081-1083. doi:10.1097/PEC.0b013e3182360674
10. Parrini E, Mei D, Wright M, Dorn T, Guerrini R. Mosaic mutations of the FLN1 gene cause a mild phenotype in patients with periventricular heterotopia. *Neurogenetics.* 2004;5(3):191-196. doi:10.1007/s10048-004-0187-y
11. Sheen VL, Dixon PH, Fox JW, et al. Mutations in the X-linked filamin 1 gene cause periventricular nodular heterotopia in males as well as in females. *Hum Mol Genet.* 2001;10(17):1775-1783. doi:10.1093/hmg/10.17.1775
12. Hidalgo-Bravo A, Pompa-Mera EN, Kofman-Alfaro S, Gonzalez-Bonilla CR, Zenteno JC. A novel filamin A D203Y mutation in a female patient with otopalatodigital type 1 syndrome and extremely skewed X chromosome inactivation. *Am J Med Genet A.* 2005;136(2):190-193. doi:10.1002/ajmg.a.30792
13. Gale RE, Wheadon H, Boulos P, Linch DC. Tissue specificity of X-chromosome inactivation patterns. *Blood.* 1994;83(10):2899-2905.
14. El Kadib A. Green and functional aerogels by macromolecular and textural engineering of chitosan microspheres. *Chem Rec.* 2020;20(8):753-772. doi:10.1002/tcr.201900089
15. Actis P, Vilozny B, Seger RA, et al. Voltage-controlled metal binding on polyelectrolyte-functionalized nanopores. *Langmuir.* 2011;27(10):6528-6533. doi:10.1021/la2005612
16. Guerrini R, Mei D, Sisodiya S, et al. Germline and mosaic mutations of FLN1 in men with periventricular heterotopia. *Neurology.* 2004;63(1):51-56. doi:10.1212/01.wnl.0000132818.84827.4d
17. Hehr U, Hehr A, Uyanik G, Phelan E, Winkler J, Reardon W. A filamin A splice mutation resulting in a syndrome of facial dysmorphism, periventricular nodular heterotopia, and severe constipation reminiscent of cerebro-fronto-facial syndrome. *J Med Genet.* 2006;43(6):541-544. doi:10.1136/jmg.2005.038505
18. Hu J, Lu J, Goyal A, et al. Opposing FlnA and FlnB interactions regulate RhoA activation in guiding dynamic actin stress fiber formation and cell spreading. *Hum Mol Genet.* 2017;26(7):1294-1304. doi:10.1093/hmg/ddx047
19. Yang C, Yang P, Liu P, et al. Targeting Filamin A alleviates ovariectomy-induced bone loss in mice via the WNT/β-catenin signaling pathway. *Cell Signal.* 2022;90:110191. doi:10.1016/j.cellsig.2021.110191
20. Hart AW, Morgan JE, Schneider J, et al. Cardiac malformations and midline skeletal defects in mice lacking filamin A. *Hum Mol Genet.* 2006;15(16):2457-2467. doi:10.1093/hmg/ddl168
21. Parrini E, Rivas IL, Toral JF, et al. In-frame deletion in FLNA causing familial periventricular heterotopia with skeletal dysplasia in males. *Am J Med Genet A.* 2011;155A(5):1140-1146. doi:10.1002/ajmg.a.33880
22. Zenker M, Rauch A, Winterpacht A, et al. A dual phenotype of periventricular nodular heterotopia and frontometaphyseal dysplasia in one patient caused by a single FLNA mutation leading to two functionally different aberrant transcripts. *Am J Hum Genet.* 2004;74(4):731-737. doi:10.1086/383094

Downloaded from https://www.neurology.org by 104.28.195.185 on 15 March 2026